

Otoplasty for Protruding Ears: Modified Technique

OMAR O. SHOUMAN, M.D.

The Department of Plastic and Reconstructive Surgery, Faculty of Medicine, Mansoura University

ABSTRACT

Background: Protruding ear is one the most common congenital deformities of which the patient seek surgical consultation.

Numerous autoplasmic techniques have been described for surgical correction of the protruding ears. Recreating the antihelical fold and lowering the auriculocephalic angle are the basic processes of achieving a normal looking ear. The aim of the present work is to present a surgical trial for correction of protruding ears using a method which is a combined Mustardé and Furnas techniques and to evaluate long terms clinical outcomes and rates of complications.

Material and Methods: The study was carried out during the period between 2011 to 2013 on 25 cases of protruding ears from patients referred to the Aesthetic and Plastic Surgery Outpatient Clinic Mansoura University Hospitals and Health Insurance Hospital. The surgical technique was carried out on 25 patients with bilateral protruding ears, 20 males and 5 females. Patients were followe-up for six months after operation.

Results: Satisfactory results were obtained in 20 cases, but early complications occurred in two cases in the form of unilateral haematoma which was treated in one case, and developed infection in the other case. Another ear developed partial recurrence which needed correction after 6 months. Late complications included scar hypertrophy and keloid formation in two patients.

Conclusion: The present work demonstrate that the combined use of the Mustardé and Furnas techniques result in a high degree of satisfaction to patients and low rate of complications.

Key Words: Otoplasty – Protruding ears.

In most patients, ear prominence relates to a combination of issues most commonly underdevelopment of the antihelix and anterior conchal rotation related to inadequate tethering of the mastoid, two less common reasons are extensively deep conchal bowl and rarely obtuse crus [1]. By adulthood, the auricle measures 5.5 to 6.5cm in length and a child will reach 85% of his length by 4 to 6 years of age, which also correlates to appropriate age to begin surgical planning [2].

Numerous techniques for correcting the protruding ear have been described in the literature, but there is no single technique widely accepted by most of the surgeons.

By 1963 the famous technique of Mustardé was developed in which the antihelical tubing was created using without excision of the cartilage [3].

In 1968 Furnas developed a method in which retroauricular soft tissues including posterior auricular muscle and ligament were resected and attached by conchomastoid sutures [4].

The aim of the present work is to evaluate a surgical trial for correction of protruding ears using a technique which is a combined Mustardé and modified Furnas procedures and to demonstrate short and long clinical outcomes and complications.

INTRODUCTION

Protruding ear is one of the most common congenital deformities for which the patients seek surgical consultation.

Having a protruding ear is not usually an indication of hearing problem. Both children and adults suffer psychological distress secondary to outside jokes due to their prominent ears.

PATIENTS AND METHODS

The study was conducted on 25 cases of bilateral protruding ears from patients referred to the Aesthetic and Plastic Surgery Outpatient Clinic, Mansoura University Hospitals and Health Insurance Hospital during the period between 2011-2013. Patients were of both sexes 20 males and 5 females, their ages ranged between 6-20 years. They were 7 adults and 18 children.

Surgical technique:

In the present study and before surgery, a detailed history was taken from each patient, along with full clinical examination including measuring of the cephalauricular angle before and after surgery, measurement of auricular protrusion is done by evaluating the mastoid helical distance at 3 levels [5].

- 1- Upper level, at the superior aspect of helix.
- 2- Middle level, at the level of external auditory canal.
- 3- Lower level, at the level of the lobule.

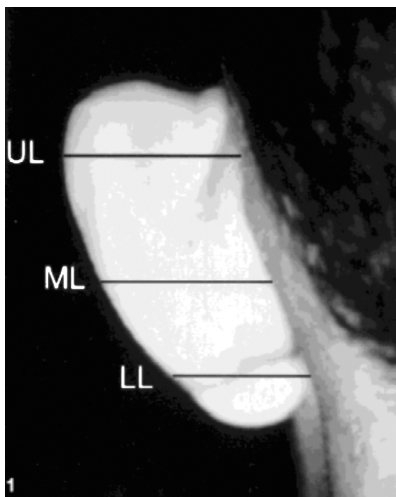


Photo (1): Evaluation of the degree of auricular protrusion at the Upper Level (UL), Middle Level (ML), and Lower Level (LL).

The surgical technique was done under general anaesthesia for 23 cases and 2 adult cases under local anaesthesia. The operative site was sterilized by antiseptic solution. To reduce bleeding intraoperatively and provide postoperative pain relief for at least 6 hours after the operation, 1% lidocaine with 1-200,000 epinephrine was infiltrated with fine needle in the postauricular subcutaneous tissue. From the posterior part of the concha, a small elliptical skin and subcutaneous tissue was excised. Subcutaneous tissue was separated from the conchal cartilage. Rasping of the exposed cartilage was done. For creation of the new antihelical fold according to Mustardé technique, the desired location of each mattress suture was marked with methylene blue.

Three interrupted 4/0 propylene sutures using round bodied needle, are required for creation of the new antihelical fold. The sutures are placed at the corresponding markings, from the retroauricular angle side through the auricular cartilage and the

perichondrium, without penetrating the ventral skin. Each suture brought the cartilage of the scapha near the concha. When the sutures are tightened they created or augmented the fold of antihelix crest by drawing the scaphoid fossa towards the concha. In conjunction with the previous Mustardé sutures technique, another technique is performed to allow permanent retraction of the auricle to the mastoid which is a modification of Furnas technique.

Three desired areas are marked for the application of three 4/0 nonabsorbable propylene sutures posteriorly. The first suture is applied at the middle of the upper third of the auricle, the second is at the middle of the second third and the last at the middle third of the lower third. These simple transverse sutures were performed to bring the conchal bowl as near as possible to the mastoid. These sutures must include the posterior perichondrium and cartilage without penetrating the anterior auricular skin. As regards the mastoid side, a good bite to the mastoid fascia should be done to avoid pulling through of the sutures and reversing the conchomastoid setback of the auricle. After careful haemostasis, the skin is closed by 5/0 monocryl sutures. Vaseline gauze is used to pack (dead spaces) in front and back of the ear, moulding the exact ear shape desired.

Then a cotton gauze is wetted with antibiotic cream and carefully placed over the new antihelical fold and concha. This dressing is maintained by a roll of gauze and light crib bandage. It is left in position for 5 days.

RESULTS

The present work was carried out on 25 patients with bilateral protruding ears (20 males and 5 females). Their aged ranges between 6-20 years, they were 7 adults and 18 children. Satisfactory results were obtained in 20 cases (80%) during the 6 months follow-up period. On measuring the cephalo-auricular angle pre and postoperatively, satisfactory results accomplished by a postoperative cephalauricular angle between 15°-20° instead of 20°-30° Preoperative.

Early complications included the development postoperative unilateral hematoma in 2 cases (4%), one is treated with saline irrigation and antibiotic with a good response, the other developed infection followed by partial resorption of the cartilage after 4 months postoperative. Late complications included occurrence of bilateral scar hypertrophy and keloid formation in two cases (8%). One patient (2%) experienced partial recurrence in one ear due

to trauma which needed further correction after 6 months.

Measurement of the degree of auricular protrusion preoperatively showed an average of 29mm at

the upper level and 26.3mm at the middle level and 22.2mm at the lower level. Postoperative measurement after ear correction revealed an average of 11.9mm upper level and 13.5mm at the middle level, and 16.1mm at the lower level.




Photo (2): Before and after.

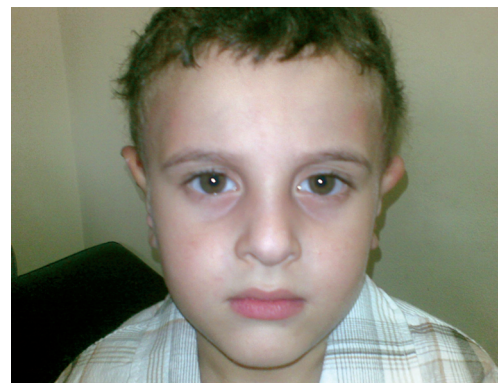



Photo (3): Before and after.

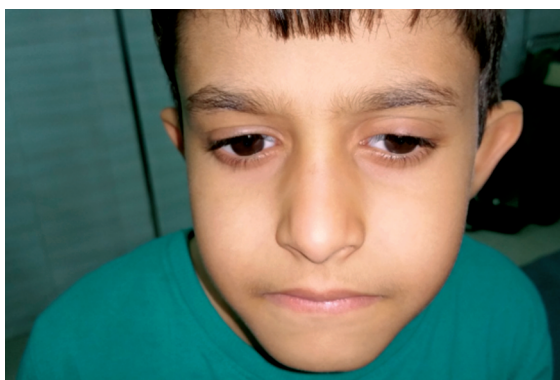

Photo (4): Before and after.

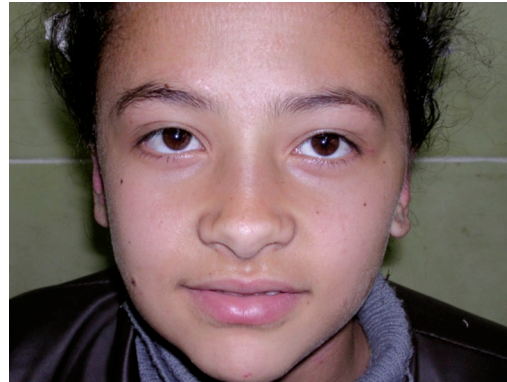

Photo (5): Before and after.

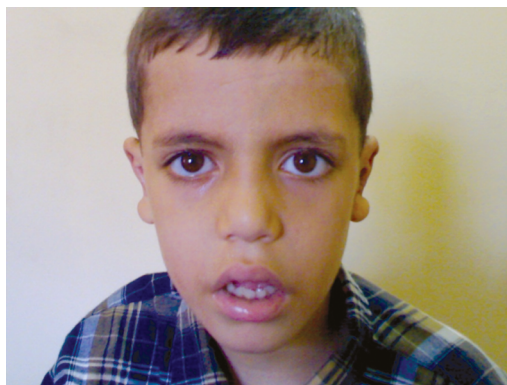
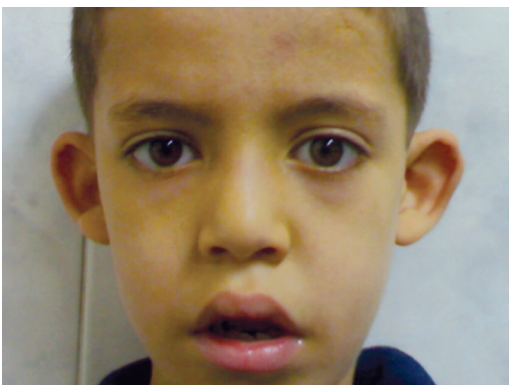


Photo (6): Before and after.

DISCUSSION

Ear reshaping is a type of cosmetic surgery for treatment of protruding ears, which may be unilateral or bilateral and may be asymmetric.

The goal of otoplasty for correction of protruding ears is normalization of shape and position of both auricles. Surgeons are committed to create a new auricle which is similar to a normal one as possible. In unilateral cases, the challenge may be greater, since the goal is to immitate as perfectly as possible the normal side [6].

Protruding ears commonly involve large concha with poorly developed antihelix and scapha. It is the result of malformation of cartilage during development in intrauterine life [7].

Numerous surgical techniques have been described and proven successful to give patient satisfaction, to the extent it is difficult to say that any new technique is necessary [8]. Those techniques focus on creating a new antihelical fold, reducing the scaphomastoid angle and trimming the concha. The first reported technique for ear correction took place in 1845 by Dienffenbach [9].

Luckett reported his technique toward restoring the antihelical fold and widening the conchoscaphal angle. Problems of this technique included the sharp antihelical border that result after surgery due to full thickness cartilage excision [10].

In 1963, the famous technique of Mustardé was developed in which the antihelical tubing was created using permanent mattress sutures without cartilage excision. In 1968, Furnas developed his original technique in which retroauricular soft tissues including posterior auricular muscle and ligament, were resected, then conchomastoid (Furnas) sutures are placed in a horizontal mattress fashion in one or two locations to approximate the conchal level to the mastoid periosteum.

In the present study, all cases of prominent ears presented by lack of antihelix and some conchal hypertrophy. The age of our patients ranged between 6-20 years. Most surgeons perform otoplasty on children who are about 5 years, but some reports stated that this operation can safely be performed at a younger age group.

Songu and Adibelli recommended otoplasty at age as young as 4 years on the assumption that,

there may be a significant psychological benefit of early intervention and after the child has expressed concern about his look [11].

In the present work, both Mustardé and Furnas sutures techniques were used for correction of the protruding ears in our patients. Some modifications were done to the original Furnas procedure which include using 3 mattress sutures along the length of the auricle instead of one or two, in the original. Resection of post auricular soft tissue was done with sparing of the muscle and ligament and resecting as little as possible of this tissue.

Both Mustardé and Furnas techniques are famous for being cartilage sparing and were developed to minimize risk of developing a sharp edge of developing a sharp edge along the antihelix. Other reasons were, first to avoid a technique irreversibly changes anatomical land marks of the auricle, and second to minimize dissection of the ear. These techniques are most useful in patients of younger age groups with soft pliable cartilage, together with mattress sutures (Mustardé) utilization to form a proper anti-helical fold and create the suitable concomastoid angle (Furnas sutures) by careful approximation of conchal bowl to mastoid periosteum. They offer the advantage of being technically simple and easily reversible with no permanent damage to the auricular cartilage. In most cases, these techniques allow the surgeon to control the shape of the created anti helical fold and the degree of the auriculomastoid angle by changing the number, the position and the amount of tension on the sutures used [6].

In the current work, partial recurrence due to trauma occurred in one ear (2%), which needed correction after 6 months. According to the mother's statement care was not taken to avoid trauma to the child's ear by maintaining position to allow correct healing. Mustardé technique even with nonabsorbable sutures not always produce stable results. The relapse rate for this technique has been reported to be 7%, which was attributed to the continued traction exerted by the cartilage recoil on the sutures that may cut across the cartilage [3,12].

When Mustardé technique was compared with the technique of Stenstrom, the recurrence rate of Mustardé was 24%, whereas 10% of Stenstrom's patients required reoperation [13]. The function of the slowly absorbed sutures used in stenstrom technique ends in a few weeks with the development of fibrosis and this explains the lower recurrence rate. On the other hand, Rigg (1979) and

Staindel stated that the use of non-absorbable sutures may lead to recurrence of the deformity [14,15].

Among the early complications of the present work is the development of unilateral haematoma in two cases 4%, one ear was treated with saline irrigation and antibiotic, with good response.

The other developed infection followed by partial resorption of the cartilage 4 months post operative. Limand jaja, et al., stated that the incidence of hematoma in their study was 1-3% and the first sign of its occurrence was severe pain. They also stated that, if haematoma was treated early, it may lead to complications as infection, cartilage necrosis and auricular deformity [16].

Since late complications, such as hypertrophic scars and keloid (8% of cases in the present study), can occur even months after otoplasty, follow-up examinations after longer intervals are recommended.

Fortunately technical advances have led to a huge decrease in problems with suture material. The modern surgeons have access to suture materials with long term biocompatibility and good knotting characteristics, so thread granuloma and inflammation have become something of a rarity. For these reasons, the author avoided all aggressive cutting or scoring techniques and used sutures techniques, not just for folding the antihelix.

The use of modified Furnas technique (three sutures instead of one or two) allowed the reduction of the cephalo auricular angle to 15°-20° and emphasizing the antihelical fold without the interruption of the contour.

REFERENCES

- 1- Handler E.B.1, Song T. and Shih C.: Complications of otoplasty. *Facial. Plast. Surg. Clin. North Am.*, 21 (4): 653-62, 2013.
- 2- Janz B.A., Cole P., Hollier L.H., Jr., et al.: Treatment of prominent and constricted ear anomalies. *Plast. Reconstr. Surg.*, 124, 2009.
- 3- Mustardé J.C.: The correction of prominent ears using simple mattress sutures. *Br. J. Plast. Surg.*, 16: 170-3, 1963.
- 4- Furnas D.W.: Correction of prominent ears by conchamastoid sutures. *Plast. Reconstr. Surg.*, 42 (3): 189-93, 1968.
- 5- Foda H.M.T.: Otoplasty: A graduated approach. *Aesth. Plast. Surg.*, 23: 407-12, 1999.
- 6- Shehab El-Din S.A.: Combined otoplasty techniques in correction of prominent ears. *Egypt. J. Plast. Reconstr. Surg.*, 27: 19-28, 2003.

- 7- Siegert R., Weerda H. and Remmert S.: Embryology and surgical anatomy of the auricle. *Facial. Plast. Surg.*, 10: 232-43, 1994.
- 8- Sivrioglu N., Irkoren S., Akosy B. and Copcu E.: Chong-Chet Anterior Scoring Technique for the Correction of Prominent Ears: Results in 30 Patients. *Modern Plastic Surgery*, 2: 39-42, 2012.
- 9- Dieffenbac J.F.: *Die Operative Chirurgie*. Leipzig: Brookhaus, p. 395, 1845.
- 10- Brenda E., Marques A., Pereira M.D. and Zantut P.E.: Otoplasty and its origins for correction of prominent ears. *J. Craniomaxillofac. Surg.*, 23 (2): 99-104, 1995.
- 11- Songu M. and Adibelli H.: Otoplasty younger than 5 years of age. *Int. J. Pediatr. Otorhinolaryngol.*, 74 (3): 292-6, 2010.
- 12- Mustardé J.C.: The correction of prominent ears using simple mattress sutures. *Br. J. Plast. Surg.*, 16: 170-8, 1963.
- 13- Tan K.H.: Long-term survey of prominent ear surgery: A comparison of two methods. *Br. J. Plast. Surg.*, 39: 270-3, 1986.
- 14- Rigg B.M.: Suture materials in otoplasty. *Plast. Reconstr. Surg.*, 63 (3): 409-10, 1979.
- 15- Staindl O.: Failure and complications following otoplasty. *Laryngol. Rhinol. Otol.*, 65 (11): 646-51, 1986.
- 16- Limandjaha G.C., Breugem C.C., Mink Van Der Molen A.B. and Kon M.: Complications of otoplasty: A literature review. *J. Plast. Reconstr. Aesthet. Surg.*, 62 (1): 19-27, 2009.